

Forensic Dental Identification Report

Postmortem Dental Chart

3 of 5

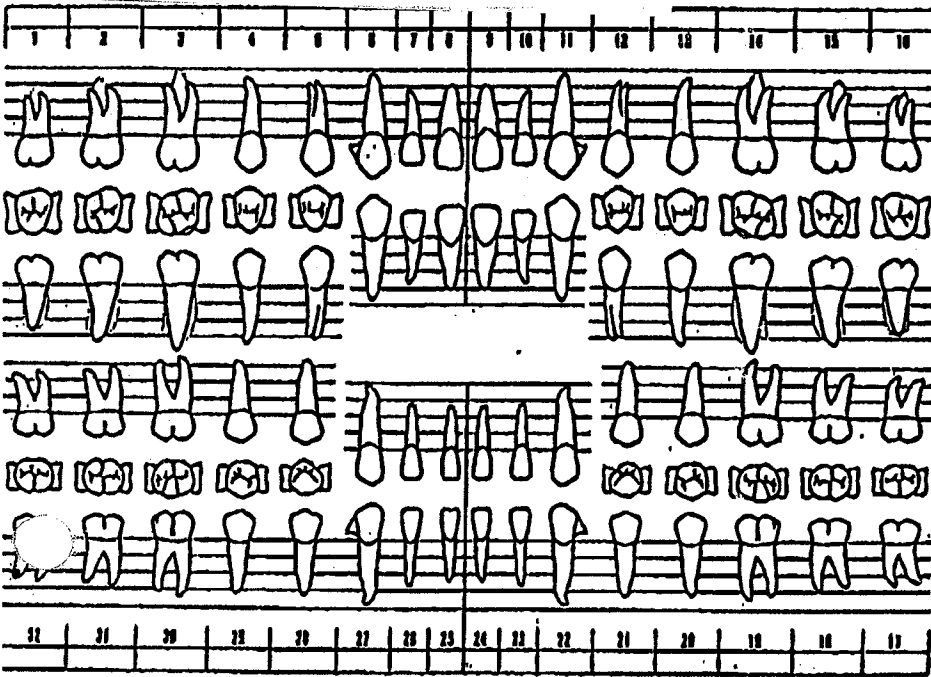
Init.: FM

Date of Exam: 4/20/98

Place of Exam: 917 N. Pines Rd., Spokane

X-ray Films Taken By: Fr. Morgan DDS

Sex:
 Oral Ac
 Chartin
 Chartin



CHARTING SYMBOLS

- | | |
|----------------------------|----------------------------------|
| AM Amalgam | CV Crown Veneered |
| GI Gold Inlay | CT Crown Temporary |
| GF Gold Foli | IR Intermediate Restoration |
| CO Composite | FP Fixed Partial |
| SS Metal of any other type | RP Removable Partial |
| JFM Jaw Fragment Missing | CD Complete Denture |
| TA Traumatic Avulsion | M Mesial |
| FX Fractured Crown | D Distal |
| PN Present not Restored | O Occlusal |
| RO Rotated | I Incisal |
| RT Root Tip | F Facial |
| RCT Root Canal Treatment | L Lingual |
| AP Apicoectomy | C Crown |
| CF Crown Full | U Unerupted |
| CP Crown Partial | X Extracted (Antemortem Missing) |
| CAR Caries | N Postmortem Missing |
| DEC Deciduous | PON Pontic |

NR = No Restoration

Sample Entry Format: MO-AM; F-AM; RO

Remarks:
 Full recovered
 4/21/98 by Spokane
 Police Dept.

FDI		UNIVERSAL		DESCRIPTION
PRIM.	PERM.	PRIM.	PERM.	
	18		1	X
	17		2	X
	16		3	MO-AM O -AM
55	15	A	4	MOD-AM
54	14	B	5	N
53	13	C	6	N
52	12	D	7	N
51	11	E	8	N
61	21	F	9	N
62	22	G	10	N
63	23	H	11	Mesial decay
64	24	I	12	DO-AM
65	25	J	13	MOD-AM
	26		14	MO-AM
	27		15	X
	28		16	X
	38		17	X
	37		18	X
	36		19	MODL-AM
75	35	K	20	NR
74	34	L	21	NR
73	33	M	22	NR
72	32	N	23	Rotated
71	31	O	24	N
81	41	P	25	N
82	42	Q	26	N
83	43	R	27	NR
84	44	S	28	Virgin - NR
85	45	T	29	DO-AM
	46		30	MOD-AM. ^{or} MODB-AM
	47		31	X
	48		32	X